

Michał Hubert Siemaszko

Patient reported problems with erectile function in last two years. Also, he reported some problems with voiding and bladder function.

Erectile test with Prostaglandine E1 confirmed 80% of erection. Anatomically, penis looks normal with mild dorsal curvature. Length is approx. 17 cm, since it was difficult to measure properly due to lack of rigidity.

Ultrasound exam: both kidneys have properly size, shape, normal echogenicity of the parenchima, without signs of dilatation or stones. Bladder is full of urine, with excessive capacity (800ml), prostate is regular, vol 15ml. Huge residual urine: 260ml.

Recommendation: Consultation with neurologist-neurourologist and endocrinologist (hormonal status, testosterone, PSA, etc..)

Will be good to start with Cialis 5mg, one tablet per day for one month, if there is no contraindication after consultation with cardiologist.


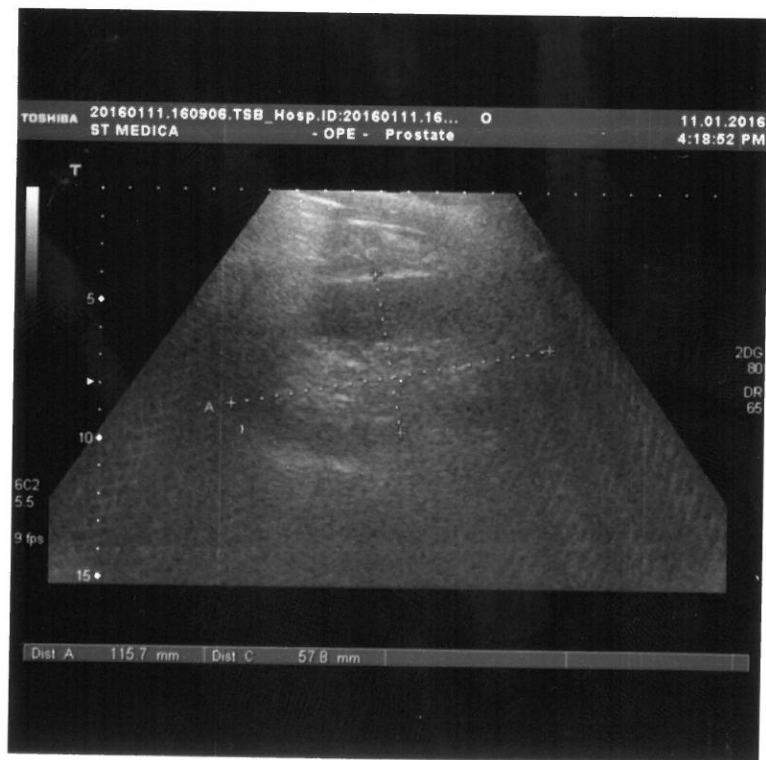
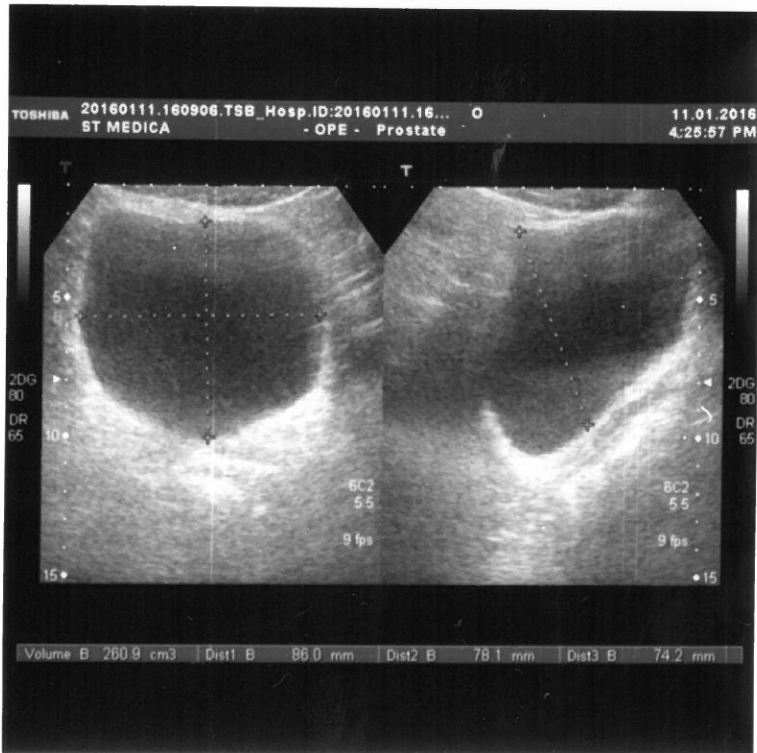
DG: Erectile dysfunction
Neurogenic bladder disorder

Next consultation is planned in one month.

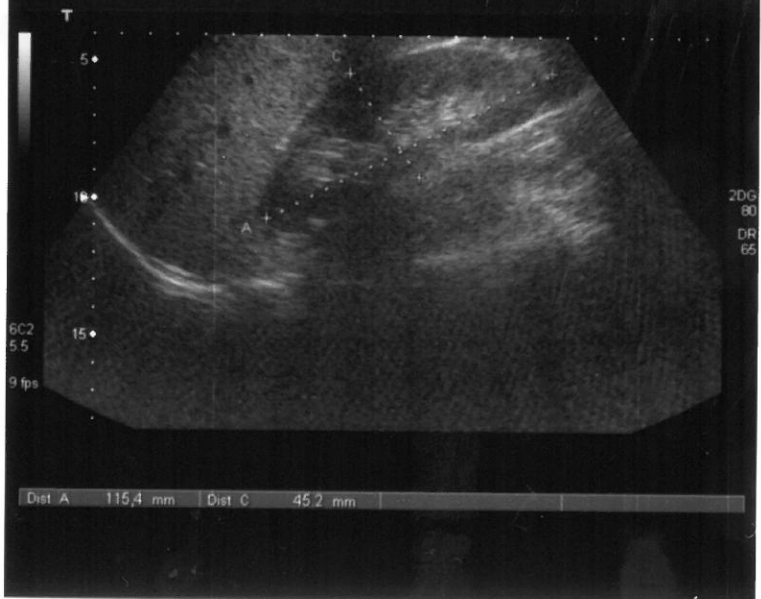
Belgrade 11th January 2016

 Prof. Dr M. Djordjevic, MD, PhD





TOSHIBA 20160111.160906.TSB_Hosp.ID:20160111.16... O 11.01.2016
ST MEDICA - OPE - Prostate 4:16:16 PM



TOSHIBA 20160111.160906.TSB_Hosp.ID:20160111.16... O 11.01.2016
ST MEDICA - OPE - Prostate 4:14:57 PM

